

# REVIEWS

Dent. Med. Probl. 2011, 48, 3, 000–000  
ISSN 1644-387X

© Copyright by Wrocław Medical University  
and Polish Dental Society

WOJCIECH BEDNARZ

## The Thickness of Periodontal Soft Tissue Ultrasonic Examination – Current Possibilities and Perspectives

### Badanie ultrasonograficzne grubości tkanek miękkich przyzębia – aktualne możliwości i perspektywy

“Medident” Specialist Outpatient Clinic, Gorlice, Poland

#### Abstract

Identification of a periodontal biotype in patients has a fundamental meaning in optimal planning of preventive and therapeutic management mainly in periodontology, orthodontics, implantology and dental prosthetics. Identification of a periodontal biotype in a specific dentogingival unit is often required. Soft tissue thickness in the periodontium, called gingival thickness (GT) is an essential factor that has influence on a periodontal biotype assessment. Invasive and non-invasive methods are utilized in its examination. Measurement of gingival thickness and the oral mucosa are most commonly carried out using a periodontal probe under local anesthesia, or by more precise method of transgingival probing (TGP) using an endodontic tool with a silicone limiter (bone sounding – BS). The computed tomography allows indeed to assess thickness of the palatal and gingival mucosa in a low invasive way, but it is an expensive and still hard to get method. An ultrasound gingival thickness measurement (UGTM) is a safe and painless method, but an appropriate instrument is required. The aim of this study is to present the prototype of Pirop<sup>®</sup> Ultrasonic Biometer and its usage in an assessment of periodontal soft tissue thickness (**Dent. Med. Probl. 2011, 48, 3, 00-00**).

**Key words:** gingival biotype, gingival thickness, ultrasonic method.

#### Streszczenie

Rozpoznanie biotypu przyzębia u pacjenta ma podstawowe znaczenie w planowaniu optymalnego postępowania profilaktyczno-leczniczego głównie w periodontologii, ortodontji, implantologii i protetyce stomatologicznej. Często wymagane jest określenie biotypu przyzębia konkretnej jednostki zębowo-dziąsłowej. Istotnym elementem wpływającym na jego ocenę jest grubość tkanek miękkich przyzębia określana jako grubość dziąsłowa (GT – *gingival thickness*). Do jej zbadania są stosowane metody inwazyjne i nieinwazyjne. Pomiar grubości dziąseł i błony śluzowej jamy ustnej najczęściej jest dokonywany w znieczuleniu miejscowym, z użyciem sondy periodontologicznej lub dokładniejszą metodą nakłuwania z wykorzystaniem narzędzia endodontycznego z silikonowym ogranicznikiem (TGP – *transgingival probing*, BS – *bone sounding*). Tomografia komputerowa pozwala wprawdzie na ocenę grubości błony śluzowej podniebienia i dziąseł w sposób mało inwazyjny, ale jest metodą drogą i wciąż trudno dostępną. Ultradźwiękowy pomiar grubości tkanek miękkich przyzębia (UGTM – *ultrasonic gingival thickness measurement*) jest metodą bezpieczną i niebolesną, ale wymagającą użycia odpowiedniego aparatu. Celem pracy jest przedstawienie prototypu biometru USG Pirop<sup>®</sup> i możliwości jego wykorzystania w badaniu grubości tkanek miękkich przyzębia (**Dent. Med. Probl. 2011, 48, 3, 00-00**).

**Słowa kluczowe:** biotyp dziąsłowy, grubość dziąsła, metoda ultradźwiękowa.

Identification of a periodontal biotype in patients has a fundamental meaning in optimal planning of preventive and therapeutic management mainly in periodontology, orthodontics, implantology and dental prosthetics. In year 1969,

Ochsenbein and Ross have indicated the occurrence of the 2 main morphologic types of gingiva, that were named a scalloped-thin and flat-thick gingival (occ. 1). Seibert and Lindhe have coined the term “periodontal biotype”, while Claffey and

Shanley have determined thickness of a gingiva typical of a – less than 1.5 mm and of a – not less than 2 mm, and they also emphasized that patients with a Greenberg et al. determined a periodontal biotype on the basis of gingival thickness measurements using a periodontal probe under local anesthesia [1, 2]. The gingiva with thickness less than 1.5 mm was classified as a thin biotype, while the gingiva with thickness  $\geq 1.5$  mm was classified as a thick biotype. However, the accuracy of the examination was not high, because measurement results were rounded to 0.5 mm. The need of proper angulation and pressure applied to tissues were additional limitations.

Wennström [3], in 1980s of the past century, has already demonstrated that a little horizontal diameter of gingival tissues might be the place of less resistance, and with the presence of a dental plaque, it could be conducive to an apical migration of a connective tissue attachment along with the marginal gingiva, especially near teeth under the influence of orthodontic forces. Also, he has demonstrated the decrease of a keratinised gingiva width is caused by loss of an apical connective tissue attachment, and do not cause a gingival recession created in that way.

Yared et al. [4] have stated that 93% of adult patients had developed a dental recession during orthodontic treatment using permanent orthodontic appliances that pull forward incisor teeth of the mandible. In these cases, the assessed thickness of the alveolar gingiva was less than 0.5 mm. Huang et al. [5] have analyzed factors that have influence on the effectiveness of a free gingival graft procedure with coronally positioned flap in 23 patients with one gingival recession on the buccal side in the mandible, that underwent surgery. The authors stated that, during 6-month follow-up, gingival recessions were completely covered when pre-surgical thickness of the gingiva was more than 1.2 mm.

Olsson and Lindhe [6] demonstrated the presence of a periodontal biotype predisposing to dental recession development. They examined the width, thickness of the keratinised gingiva and an incisor teeth shape in the mandible to determine the periodontal biotype. The long and narrow crowns of the clinically medial incisor teeth in the mandible, that also have simultaneously the narrow and thin alveolar gingiva, have a thin periodontal biotype. According to the authors, the probability of gingival recession development is high with the thin periodontal biotype accompanied by other risk factors. Müller and Eger [7] found a clinical condition named the thin periodontal biotype by Olsson and Lindhe, in the 66.6% cases of 42 patients. The thin gingival biotype with wide area of the

keratinised gingiva with its higher thickness, and square superior incisor teeth were found in the 21.5% of cases. The third classified biotype found in 11.9% cases of the studied group, has a narrow, but normal in thickness keratinized gingiva and a crown width/length ratio of the superior incisor teeth near the value of one.

Kan et al. [8] have presented a simple method of periodontal type determination, which utilizes translucency of the free gingiva during the probing of gingival grooves in teeth. The biotype is thick, when during an examination, the periodontal probe is not visible through a gingiva. The biotype is reported as thin, when the periodontal probe is visible through a gingiva.

In epidemiological studies performed on population of the 230 youths aged 17, from small and big towns, Bednarz et al. [9] have found a gingival recession in 21% of them. Of the 67 observed cases of gingival recessions, only 18 of them have height above 2 mm. However, subclinical lesions were observed in the 157 dentogingival units. The gingival margin was located on the cemento enamel *junction, or slightly in coronal direction, and the location of a connective tissue attachment has displacement of 1 mm, from the cemento enamel junction, in the coronal direction at the CAL probing depth.* Although, the authors did not perform the assessment of the alveolar gingival thickness, but they emphasize such locations are potentially at risk of gingival recession development in the future. Therefore, the authors propose to group patients in a growing age with higher risk of dental recession development ( thin biotype group).

De Rouck et al. [10] made an assessment of 100 patients with normal periodontium for determination of a periodontal biotype. It was determined according to an assessment of the width to length ratio (CW/CL) in the medial incisor teeth in the mandible, the interincisor height of a gingival papilla (PH), the width of the keratinized gingiva (KT), and thickness of a gingiva measured by Kan, using a periodontometer while probing the transparency. The thin periodontal biotype occurred in as many as 37% of cases. The mean CW/CL ratio was 0.79, PH ratio was 4.29, KT ratio was 4.92, and in all cases during the probing, the periodontal probe was visible. 29% of patients have the thick and thin biotype (CW/CL = 0.88, PH = 4.84, KT = 5.84, no gingival transparency in 83%). On the other hand, 34% of examined cases have the thick and arched biotype (no gingival transparency in 97%, CW/CL = 0.77, PH = 4.54, KT = 5.20). Intra-oral photographs were made in all patients. Based on them, the periodontal biotype was assessed by 5 general dentists, 5 periodontologists and 5 dentistry students, that were invited to the experiment

[11]. Less than the 50% of biotypes were correctly assessed, also by experienced dentists. The thin periodontal biotype was recognized by general dentists in barely 52% of patients, by students in 57% of patients, and by periodontologists in 61% of patients. The result of the study indicates not only the need of determination of the periodontal type, but also still a little knowledge on this field in dentists.

## Gingival Thickness Measurement

However, in clinical practice, identification of a periodontal biotype in a specific dentogingival unit is most often required. Soft tissue thickness in the periodontium, called gingival thickness (GT), is an essential factor that has influence on a periodontal biotype assessment. Invasive and non-invasive methods are utilized in its examination. A measurement of thickness of gingiva and the oral mucosa are most commonly carried out using a periodontal probe under local anesthesia [12, 13] or by more precise method of transgingival probing (TGP) using an injection needle or an endodontic tool with a silicone limiter (BS – *bone sounding*) [14, 15]. The computed tomography allows indeed to assess thickness of the palatal and gingival mucosa in a low invasive way, but it is an expensive and still hard to get method [16–18]. Ueno et al. [18] have examined the oral mucosa thickness in the oral vestibule, palate and regions without teeth in 5 corpses with the invasive method, using the CBCT. The authors made an analysis of linear regression and correlation in the range of both methods measurement accuracy, and they found a high level of correlation between them ( $r = 0.90$ ;  $P < 0.01$ ). The measurement error was  $0.52 \pm 0.36$  mm. The investigators suggest to use this technique in determination of soft tissue thickness in implantology, where it is often required for 3D visualization of skeletal conditions, because of a high radiation dose received by an examined patient.

An ultrasound gingival thickness measurement (UGTM) is a safe and painless method, but an appropriate instrument is required [19–22]. It is not a new method. B-scan ultrasonic probe with 10 MHz frequency, with head diameter of 5 mm, were utilized so far [22]. They allowed to conduct one-point measurement of a gingiva. Müller et al. [20, 21] used the SDM A-scan instrument (Sonic Device Measurement) for measurements, with the A-scan head with 5 MHz frequency, an initial delay of  $0.3 \pm 0.2$  ms and ultrasonic impulse velocity of 1514 m/s. The front of the head had 4 mm

in diameter. The inaccuracy of such ultrasonic examination was about 25%. The authors of the papers emphasized also difficulties in obtaining the results of measurements, because of inability to obtain a perpendicular positioning of a probe to uneven basis of a bone in many cases.

The aim of this study is to present the prototype of Pirop® Ultrasonic Biometer and its usage in an assessment of periodontal soft tissue thickness.

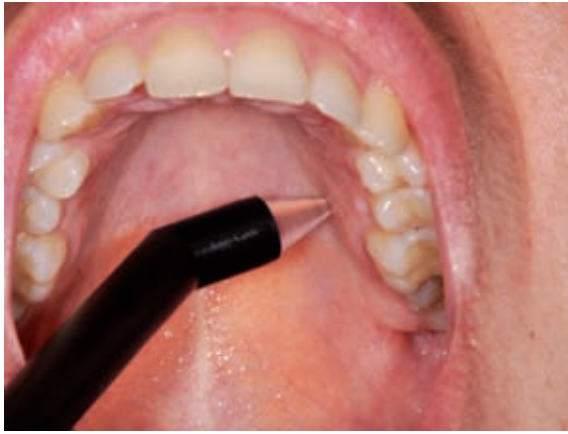## Presentation the Prototype of Periodontal USG Biometer

Pirop® Ultrasonic Biometer is the instrument with the A-scan probe with 20 MHz frequency, intended to measure thickness of soft tissues, that cover bones and teeth in the oral cavity, in the range 0.25 to 6 mm, and accuracy up to 0.01 mm (Fig. 1). The round front of the tapered head has 1.7 mm in diameter, and allows to conduct measurements in specific locations. The 45-degree angle between the probe's handpiece and the tip allows a precise positioning of the head at 90 degrees with respect to the bone base (Fig. 2). The ultrasound head is located in an examined region, touching the mucosa, but without applying pressure. Duration of return of echo from an ultrasonic impulse in the single measurement is calculated to distance, passed with 1540 m/s velocity, that is thickness of the examined mucosa. The return of the impulse and obtaining the result is impossible, when the head is positioned perpendicularly with respect to the base. That method ensures the ab-



Ryc. 1. Wygląd ogólny biometru Pirop

Fig. 1. General view on Pirop ultrasonic biometer



**Ryc. 2.** Głowica aparatu USG Pirop podczas badania grubości błony śluzowej podniebienia twardego

**Fig. 2.** The head of Pirop ultrasonic biometer during examination of palatal masticatory mucosa thickness

sence of a measurement error often made by inexperienced dentists in the bone sounding method, especially in assessment of mucosa thickness in the hard palate. It consists in oblique positioning of the endodontic instrument in relation to the bone base, that causes false, overestimated reading of a thickness value.

In the basic kit of Pirop, the manufacturer provides the instrument with 5.7-inch colour LCD touch display, ultrasonic head with 20 MHz fre-

quency, power adapter, foot pedal, thermal graphic printer with the connecting cable, and all of the elements are placed in plastic case, secured in compartments made of hard sponge (Fig. 3). Total weight of the complete kit slightly exceeds 1 kg, while the Pirop instrument weights itself 0.84 kg, and its dimensions are 199 × 154 × 84 mm. The biometer is powered by 12 V direct current from the 230 V ± 10%, 50 Hz external AC adapter that consumes 10 W per 1 hour of operation. It meets the security requirements of the II class of protection according to the following standards: Medical Device Directive 93/42 EEC, EMC Directive 89/336/EEC, Electromagnetic Compatibility EN 60601-1-2, Electrical Safety IEC 601.

The instrument allows to conduct contact measurements of the oral mucosa thickness calculate an arithmetic mean and standard deviation, that could be stored in a printed document using the printer from the kit. The on-screen diagram resulting from a measurement and parameters can be also stored in an external memory. A small internal memory does not allow to save measurement data, and saving on an external medium is required. Therefore, it is possible to create investigator's data and his settings, that are saved, and also patient data and to store information about the date and time. It is possible to print a document or image in the BMP file type, that is stored on the



**Ryc. 3.** Podstawowy zestaw Pirop umieszczony w plastikowej walizce

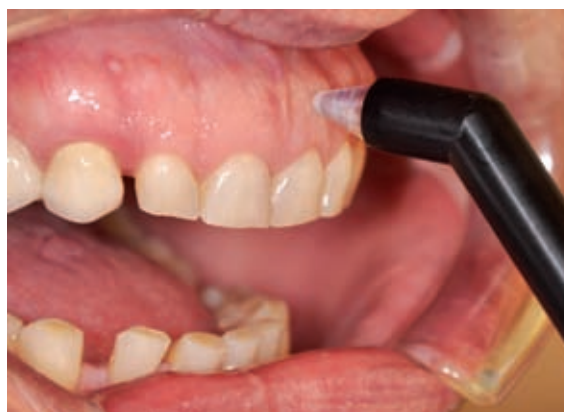**Fig. 3.** The basic kit of Pirop are placed in plastic case

external memory – a pendrive, after connecting the printer and/or external disk to the USB port at the back side of the instrument, and choosing a proper option on the screen. A folder named Pirop is automatically created on a pendrive, and subsequent images are saved inside it. In order to name them, a screen with alphanumeric keyboard is displayed, allowing to save items, after pressing the virtual key USB MEMORY. Next, the data can be transferred to a patient data base on the PC. It is also possible to update the instrument by the USB port, and the file with update can be sent inside an e-mail message.

Individual study parameter settings could be set by 9 users in the demonstrated instrument. After typing in an user number, it is possible to set time delay individually from the start of a measurement, with the START key, till the beginning of sending and calculating of ultrasonic impulses. A range of delay is between 1 to 9 seconds. It is also feasible to set velocity of an ultrasonic impulse in a range from 1400 to 2000 m/s. The default instrument setting for a measurement start delay is 2 seconds, and for impulse velocity is 1540 m/s. Choosing the DEFAULT key and answering yes to a question: SET DEFAULT SETTINGS? will restore default settings. Setting the appropriate echo gain is possible with selecting the page with a measurement named MEASURES from the main menu. A decrease of an excessive gain and an increase of an insufficient gain can be obtained by operating the GAIN  $\pm$  buttons. An individually set gain is not held in the memory when conducting a subsequent measurement. A default value of gain is set at the 95% level.

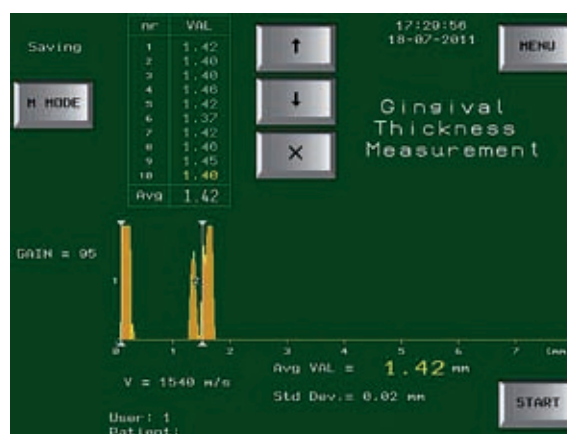
During a period of 1–2 seconds, 10 measurements are done, after the instrument is powered on by the foot pedal or directly with the touch screen, with the investigator set delay in a range of 2 to 9 seconds in order to obtain an optimal positioning of the head on the mucosa (Fig. 4a). An average measurement value is automatically determined (4b). A standard deviation has a preset maximal allowed value of 0.05 mm, and when the value is exceeded, a proper message with a request to make a remeasurement, or request to delete manually the most extreme values of the examination, using the specific keys, are displayed on the desktop (Fig. 5). If the standard deviation are in the range of allowed values after the manual correction, the messages disappear from the screen, and a displayed mean value of a measurement can be saved on the patient's card (Fig. 6). The same things are done after doing a proper remeasurement (Fig. 7).

The manufacturer suggests using a dedicated gel, which should be applied in space between



**Ryc. 4a.** Głowica aparatu USG Pirop podczas badania grubości dziąsła przedsionkowego

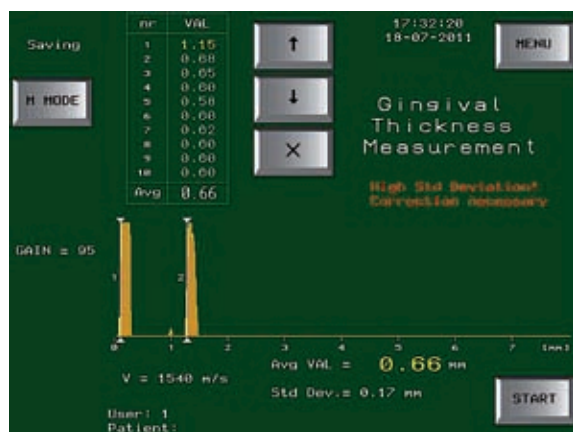
**Fig. 4a.** The head of Pirop ultrasonic biometer during examination of vestibular gingiva thickness



**Ryc. 4b.** Wykres z rezultatami pomiarów z ryc. 4a powstający na ekranie monitora, średnia wartość grubości dziąsła i odchylenie standardowe

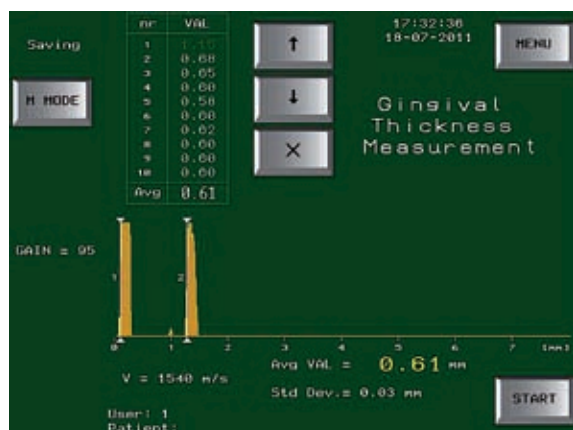
**Fig. 4b.** The on-screen diagram resulting from a measurements with Fig. 4a, average value of gingival thickness and standard deviation

a front of the head and an examined tissue, to eliminate unnecessary errors. The authors use the widely available dental gel with the chlorhexidine for conducting measurements. A complete non-invasiveness during an ultrasonic examination of mucosa thickness is an additional advantage. An examination done without local anesthesia allows a patient to feel an excessive pressure, that is applied with the head on tissues, and this is essential to preserve its accuracy. However, it must be remembered the all instrument functions are designed to facilitate the measurement process, and the dentist must personally assess measurement reliability. An examination should be repeated, when obtained results are far beyond the normal limits. If an examination of a patient using the Ultrasonic Biometer is not feasible because of any reasons, other measurement method should be utilized.



**Ryc. 5.** Wysokie odchylenie standardowe. Komunikat informujący o potrzebie powtórzenia pomiarów lub odrzucenia ekstremalnych wartości

**Fig. 5.** High standard deviation. The message appear with a request to make a remeasurement, or request to delete manually the most extreme values of the examination

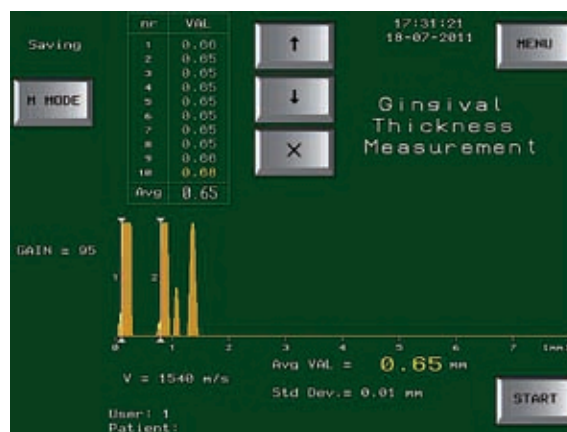


**Ryc. 6.** Wykres z rezultatami pomiarów powstający na ekranie monitora po manualnej korekcie. Znika komunikat o zbyt wysokim odchyleniu standardowym

**Fig. 6.** The on-screen diagram with measurement values after manual correction. The message about high standard deviation disappears from the screen.

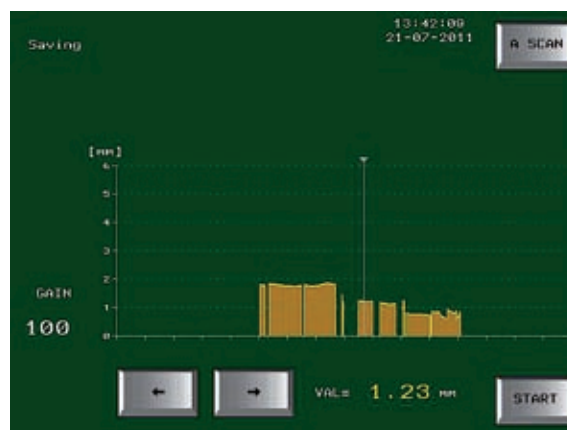
## Perspectives

In near perspective, it would be very interesting to define the thickness of free marginal gingiva, overalveolar, alveolar gum and mucosa for each teeth in labial or lingual side. Actually new M-mode "oscilloscopic" presentation is investigated. The on-screen diagram is appeared with perpendicular axis meaning thickness (mm) and horizontal meaning time (in s). From left to right side of screen run a vertical cursor with speed 8 s/screen or 16 s/screen. During measurement of gingival tissue thickness, the diagram is drawn by



**Ryc. 7.** Wykres z rezultatami pomiarów powstający na ekranie monitora po wykonaniu prawidłowego pomiaru

**Fig. 7.** The on-screen diagram with measurement values after doing a proper remeasurement



**Ryc. 8.** Prezentacja M-mode grubości dziąsła zrogowaciałego od brzegu dziąsła (od lewej) do ruchomej błony śluzowej wyrostka zębodołowego. Wykres z rezultatami pomiarów i wyświetloną wartością w miejscu położenia kursora

**Fig. 8.** M-mode presentation of keratinized gingiva thickness from marginal gingiva (left) to movable mucosa of alveolar process. The on-screen diagram and value of result from a measurement in cursor place is projected

cursor in function time. It allows to show parameters of thickness in one or many places during moving the probe for example from gingival margin to behind the mucogingival junction (Fig. 8). After ending of measure, STOP button need to be clicked and than cursor is stopped. The on-screen value of result from a measurement in this place is projected. Below diagram buttons with left and right arrows are appeared. Using them, the cursor could be movable in the other place of diagram and value of soft tissue thickness measuring in this site is showed.

Salmon et al. [23] in this year presented an ultrasound brightness-mode (B-mode) prototype device with 25-MHz high frequency. The transducer is a 3.6-mm-diameter single lead zirconate titanate ceramic (PZT) block immersed in a coupling liquid inside the chamber (15 × 18 mm) closed by a 0.2-mm 8BK membrane. The authors showed that tooth, implants surface, alveolar bone and surrounding soft tissue of periodontium are good visible. In this way the periodontal biological width, gingival thickness, bone dehiscences are identifiable and measurable. This ultrasound presentation allows positioning of the mucogingival border in about 80% of cases because the keratinized gingiva reflection appears to have an explicit echogenicity compared to the

movable mucosa. The exploration of the lower lip ultrasound confirms the thick liquid contained in the mucocele. Lodder et al. [24] propose using an B-scan ultrasonic device connecting with biopsy in early tumour cancer diagnostics. Measurement of tumour size allows to define accurate resection border. Raghav et al. [25] presented a possibility of ultrasound usage in diagnosing periapical lesions.

Ultrasonic A presentation mainly allows measuring and monitoring of periodontal mucosa thickness in prophylaxis and periodontal treatment. Ultrasound B visualization additionally offers new possibilities for prevention, diagnosis and therapeutic monitoring of periodontal diseases and oral mucosa pathologies.

## References

- [1] CLAFFEY N., SHANLEY D.: Relationship of gingival thickness and bleeding to loss of probing attachment in shallow sites following nonsurgical periodontal therapy. *J. Clin. Periodontol.* 1986, 13, 654–657.
- [2] GREENBERG J., LASTER L., LISTGARTEN M.A.: Transgingival probing as a potential estimator of alveolar bone level. *J. Periodontol.* 1976, 47, 514–517.
- [3] WENNSTRÖM J.L.: Lack of association between width of attached gingiva and development of gingival recession. A 5-year longitudinal study. *J. Clin. Periodontol.* 1987, 14, 181–184.
- [4] YARED K.F.G., ZENOBIO E.G., PACHECO W.: Periodontal status of mandibular central incisors after orthodontic proclination in adults. *Am. J. Orthodont. Dentofac. Orthop.* 2006, 130, 6.e1–6.e8
- [5] HUANG L-H., NEIVA R.E.F., WANG H-L.: Factors affecting the outcomes of coronally advanced flap root coverage procedure. *J. Periodontol.* 2005, 76, 1729–1734.
- [6] OLSSON M., LINDHE J.: Periodontal characteristics in individuals with varying form of the upper central incisors. *J. Clin. Periodontol.* 1991, 18, 78–82.
- [7] MÜLLER H.P., EGER T.: Gingival phenotypes in young male adults. *J. Clin. Periodontol.*, 1997, 24, 65–71.
- [8] KAN J.Y., RUNGCHARASSAENG K., UMEZU K., KOIS J.C.: Dimensions of peri-implant mucosa: An evaluation of maxillary anterior single implants in humans. *J. Periodontol.* 2003, 74, 557–562.
- [9] BEDNARZ W., HERBA G., ŚLEBODA A.: Badania epidemiologiczne recesji dziąsłowych u 17-letniej młodzieży z Rzeszowa i Gorlic. *Magazyn Stomatol.* 2003, 13, 51–55.
- [10] DE ROUCK T., EGHBALI R., COLLYS K., DE BRUYN H., COSYN J.: The gingival biotype revisited: transparency of the periodontal probe through the gingival margin as a method to discriminate thin from thick gingiva. *J. Clin. Periodontol.* 2009, 36, 428–433.
- [11] EGHBALI A., DE ROUCK T., DE BRUYN H., COSYN J.: The gingival biotype assessed by experienced and inexperienced clinicians. *J. Clin. Periodontol.* 2009, 36, 958–963.
- [12] WARA-ASWAPATI W., PITIPHAT W., CHANDRAPHO N., RATTANAYATIKUL C., KARIMBUX K.: The thickness of palatal masticatory mucosa associated with age. *J. Periodontol.* 2001, 72, 1407–1412.
- [13] VANDANA K.L., SAVITHA B.: Thickness of gingiva in association with age, gender and dental arch location. *J. Clin. Periodontol.* 2005, 32, 828–830.
- [14] DA SILVA S.C., JOLY J.C., DE LIMA A.F.M., TATAKIS D.N.: Root coverage using the coronally positioned flap with or without a subepithelial connective tissue graft. *J. Periodontol.*, 2004, 75, 413–419.
- [15] STUDER S.P., ALLEN E.P., REES T.C., KOUBA A.: The thickness of mucosa in the human hard palate and tuberosity as potential donor sites for ridge augmentation procedures. *J. Periodontol.* 1997, 68, 145–151.
- [16] JI-EUN S., YOO-YUNG U., CHANG-SUNG K., SEONG-HO CH., KYOO-SUNG CH., CHONG-KWAN K., JUNG-KIU CH., UI-WONG J.: Thickness of posterior palatal masticatory mucosa: the use of computerized tomography. *J. Periodontol.* 2008, 79, 406–412.
- [17] FU J-H., YEH CH-Y., CHAN H-L., TATARAKIS N., LEONG D.J.M., WANG H-M.: Tissue biotype and its relation to the underlying bone morphology. *J. Periodontol.* 2010, 81, 569–574.
- [18] UENO D., SATO J., IGARASHI C., IKEDA S., MORITA M., SHIMODA S., UDAGAWA T., SHIOZAKI K., KOBAYASHI M., KOBAYASHI K.: Accuracy of oral mucosal thickness measurements using spiral computed tomography. *J. Periodontol.* 2011, 82, 829–836.
- [19] EGER T., MÜLLER H.P., HEINECKE A.: Ultrasonic determination of gingival thickness. Subject variation and influence of tooth type and clinical features. *J. Clin. Periodontol.* 1996, 23, 839–845.
- [20] MÜLLER H.P., STAHL M., EGER T.: Dynamics of mucosal dimensions after root coverage with a bioresorbable membrane. *J. Clin. Periodontol.* 2000, 27, 1–8.
- [21] MÜLLER H.P., SCHALLER N., EGER T., HEINECKE A.: Thickness of masticatory mucosa. *J. Clin. Periodontol.* 2000, 27, 431–436.

- [22] KONOPKA T., DOMINIAK M., ĆWIRKO M.: Wpływ metod chirurgicznego pokrywania recesji dziąsłowych na grubość dziąsła właściwego. *Czas. Stomat.* 2002, 626–633.
- [23] SALMON B., LE DENMAT D.: Intraoral ultrasonography: development of a specific high-frequency probe and clinical pilot study. *Clin. Oral Invest.* DOI 10.1007/s00784-011-0533-z.
- [24] LODDER W.L., TEERTSTRA H.J., TAN I.B., PAMEIJER F.A., SMEELE L.E., VAN VELTHUYSEN M.L., VAN DEN BREKEL M.W.: Tumour thickness in oral cancer using an intra-oral ultrasound probe. *Eur Radiol.* 2011, 21, 98–106.
- [25] RAGHAV N., REDDY S.S., GIRIDHAR A.G., MURTHY S., YASHODHA DEVI B.K., SANTANA N., RAKESH N., KAUSHIK A.: Comparison of the efficacy of conventional radiography, digital radiography, and ultrasound in diagnosing periapical lesions. *Oral Surg. Oral Med. Oral Pathol. Oral Radiol. Endod.* 2010, 110, 379–385.

**Address for correspondence:**

Wojciech Bednarz  
“Medident” Specialist Outpatient Clinic in Gorlice  
Okulickiego 19, 38-300 Gorlice  
Poland  
Tel.: +48 603 962 761  
E-mail: wojcie\_ch@poczta.onet.pl

Received: 22.07.2011

Revised: 29.08.2011

Accepted: 5.09.2011

Praca wpłynęła do Redakcji: 22.07.2011 r.

Po recenzji: 29.08.2011 r.

Zaakceptowano do druku: 5.09.2011 r.